

Hepatobiliary and Pancreatic Malignancies

Diagnosis, Medical and Surgical Management

Editors:

N.J. Lygidakis

G.N.J. Tytgat

with the cooperation of

M.N. van der Heyde

B. Kremer

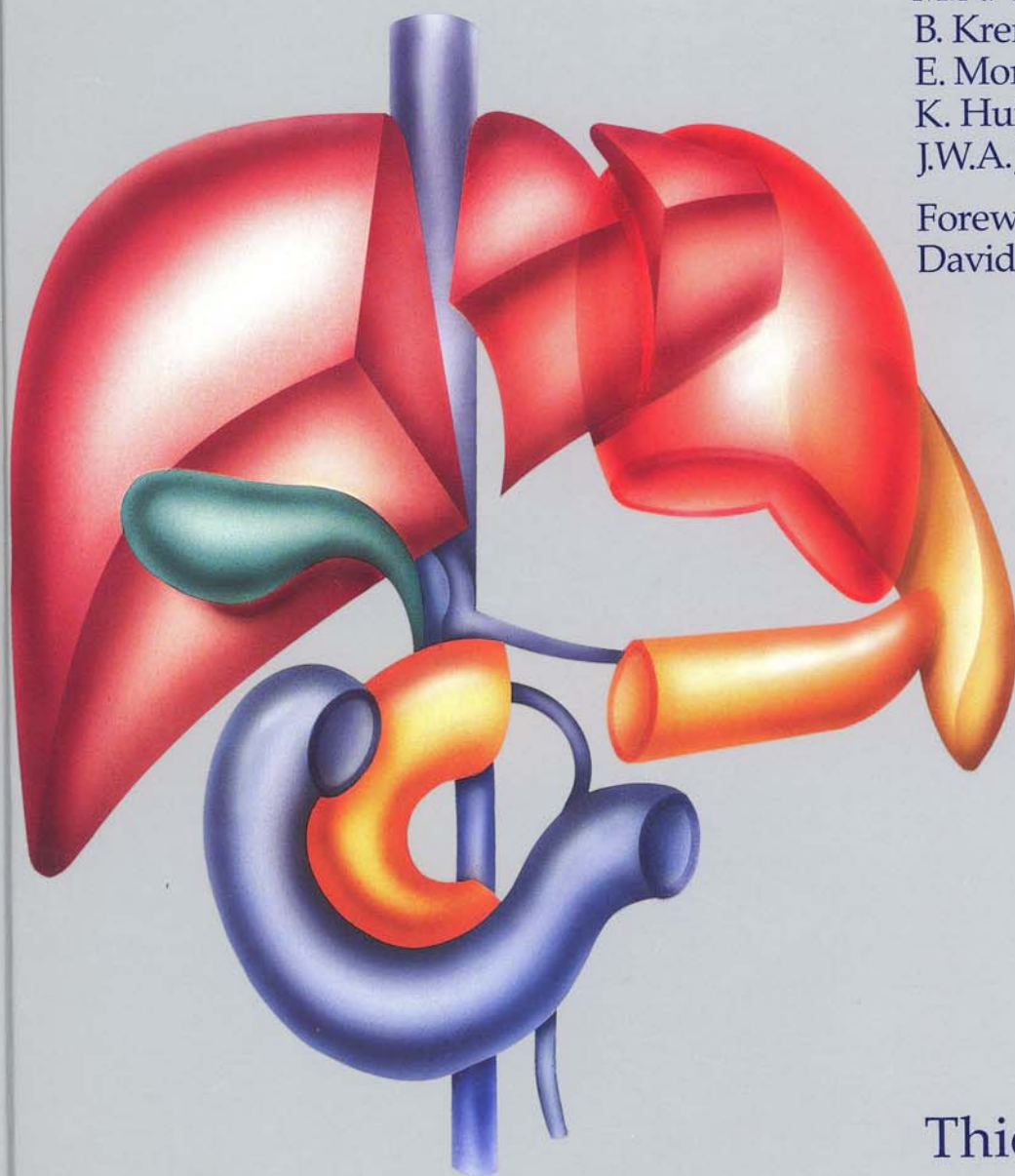
E. Moreno González

K. Huibregtse and

J.W.A.J. Reeders

Foreword by

David Skinner



Thieme

10.7 Therapeutic Alternatives in Liver Metastases

K.R. Aigner

Introduction

Liver metastases indicate poor life expectancy when there is no chance of curative treatment by extended resection. Survival depends on the number and size of the metastases as well as on their proliferation rate and location. As is well-known, most metastatic tumors in the liver are more or less resistant to any kind of chemotherapy. A number of treatment modalities have so far been tried, with varying success. Perfect technique and fundamental knowledge of the kind of treatment applied is mandatory to guarantee an optimal result.

When microwave-induced heat is applied to large metastases, they heat up selectively, since their neovasculature collapses at temperatures above 42°C. However, small metastases and micrometastases are usually cooled down again by the blood stream (Skibba et al. 1988). Hyperthermic treatment by heating up the blood stream in an extracorporeal circuit is therefore virtually useless, since it is limited by the maximum tolerable blood temperature. This itself can already cause intimal damage to the perfused arteries (Aigner et al. 1985).

Among a number of local chemotherapy techniques, chemoembolization is considered a very selective and highly effective treatment for hepatic primaries and for metastases from carcinoma or melanoma. Temporary ischemia is induced by injecting microparticles (starch microspheres, Gelfoam, angiostat) and one to three drugs (mitomycin C, doxorubicin, cisplatin) into the hepatic artery (Stagg et al. 1987).

The principle of delivering high total doses of drugs to a tumorous area in order to achieve high local tissue concentrations has been put into practice in various techniques of arterial drug supply using implantable port catheters, implantable pumps (Boddie et al. 1988, Hohn et al. 1988) and isolated perfusion techniques with a heart-lung machine (Aigner et al. 1988b, 1984, Link et al. 1985). Clinical results in local chemotherapy procedures are closely related to surgical or radiological catheter techniques and knowledge of the vascularization and chemosensitivity of the tumors treated, as well as knowledge of the pharmacokinetics and pharmacodynamics of the drugs being used. Not all tumors respond to the same drug. Most drugs which are active *in vitro* show a steep dose-response relationship. Whether a drug is active or not can therefore not be estimated merely according to the results following intravenous application (where there is a subsequent dilution to a low concentration in the total body blood vol-

ume). As soon as the total dose increases, serum drug levels and, as a consequence, tissue levels increase too (Aigner et al. 1987). A correlation between tissue drug levels and the response, demonstrated by a decrease in tumor markers, has been observed in an ongoing study (Aigner et al. 1988a, Kemeny 1988). The easiest way to increase tissue drug levels is to administer the drug intra-arterially.

Treatment Modalities and Indications

Various local treatment modalities have been developed. Hepatic arterial infusion (HAI) is considered the easiest technique for local drug delivery. The drugs are administered via radiologically or surgically placed catheters. Fluorouracil (5-FU), mitomycin C (MMC), doxorubicin, mitoxantrone and cisplatin are well tolerated by the liver parenchyma (Aigner et al. 1988b, Aigner 1988). Total doses are usually limited by their systemic toxicity, except for 5-fluoro-2-deoxyuridine (FUDR), for which the liver has a high extraction rate. However, the high local toxicity of FUDR, which causes sclerosing cholangitis, restricts its use (Hohn et al. 1987, 1988). Although there is a high total response rate of between 60 and 80% in HAI, the complete remission/partial remission (CR/PR) ratio is relatively low, and local recurrences also often originate from metastases showing partial response. Moreover, extrahepatic metastases develop in a large number of patients even after a good local response in the liver. A genuine advantage from HAI for survival has therefore not yet been demonstrated, although the response rate is higher, and the disease-free interval is longer than with systemic chemotherapy (Hohn et al. 1987). The quality of life is better with local chemotherapy, and patients with metastatic lesions close to the hepatic portal certainly benefit from HAI with regard to survival time, since even a slight shrinkage of the central metastases can prevent biliary obstruction. A high CR/PR ratio, with complete eradication of all tumor cells, is aimed for in HAI. The crucial point is how to increase the first-pass extraction of drugs, increasing the dosage without increasing the drug levels in the systemic circulation and thus the systemic toxicity.

Isolated liver perfusion (ILP) involves complete isolation of the liver in an extracorporeal circuit using a heart-lung machine. This technique demands surgical expertise and teamwork, and should only be applied in cases of disseminated liver disease without hepatomegaly. Hepatomegaly in-

volves a high incidence of extrahepatic lesions which would be outside the region treated in ILP and would thus remain unaffected by the therapy.

Hepatic arterial infusion and venous drug filtration (HAI-F), a new concept, is based on hemoperfusion or ultrafiltration of drugs. A higher than normal total dose is administered intra-arterially in order to increase the area under the curve and the tissue uptake. The active load in the systemic venous outflow behind the tumor area is decreased by passing the blood through a filter (Fig. 10.7.11).

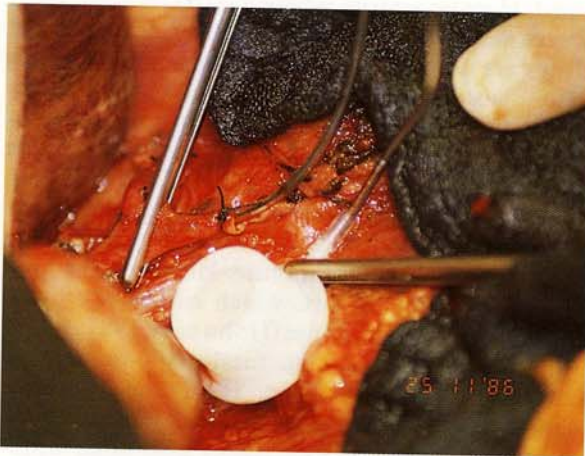


Fig. 10.7.1 An Implantofix hepatic artery catheter in the gastroduodenal artery which is clamped at its origin from the common hepatic artery for catheter implantation

Hepatic Arterial Infusion

HAI can either be performed using the Seldinger technique radiologically, or surgically, using implantable devices. Arteriography via the celiac axis and the mesenteric artery is usually performed to plan the surgical approach. Since little more than 50% of patients have a normal blood supply through one hepatic artery originating from the celiac axis, accurate knowledge of the anatomy is mandatory for catheter placement.

Operative Procedure

Through a midline incision, the common hepatic artery is exposed in the hepatoduodenal ligament. Care must be taken to dissect the hepatic artery and ligate and divide collateral branches to the duodenum and stomach. Otherwise severe gastritis, duodenitis or ulcers may occur following drug delivery. The gastroduodenal artery is then ligated distally and, through a transverse incision close to the ligature, the tip of the catheter is inserted and fixed with one or two non-resorbable ligatures. The tip should be located just inside the gastroduodenal artery where it branches off from the common hepatic artery (Fig. 10.7.1). Valve-tip catheters (Jet Port, Implantofix) need not be flushed for prophylaxis of clotting. Homogeneous perfusion of the entire liver is then checked with fluorescein or an injection of 5–10 ml of blue dye while the common hepatic artery is clamped (Fig. 10.7.2). If the blue demarcation is incomplete, anatomic variations such as a substitute left or right hepatic artery from the left gastric or superior mesenteric arteries have to be excluded. Accessory left or right arteries can

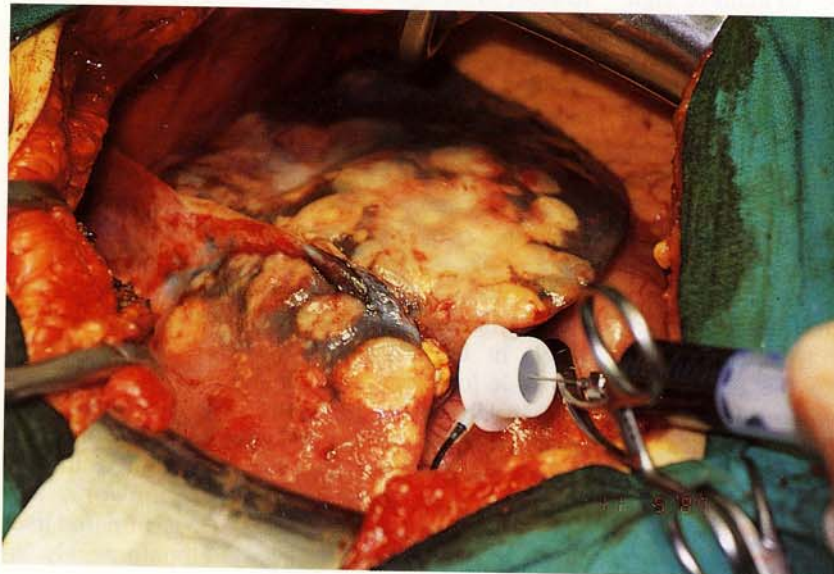


Fig. 10.7.2 A patient with a substitute right hepatic artery. Blue dye, injected through a catheter in the gastroduodenal artery, only appears in the left liver lobe

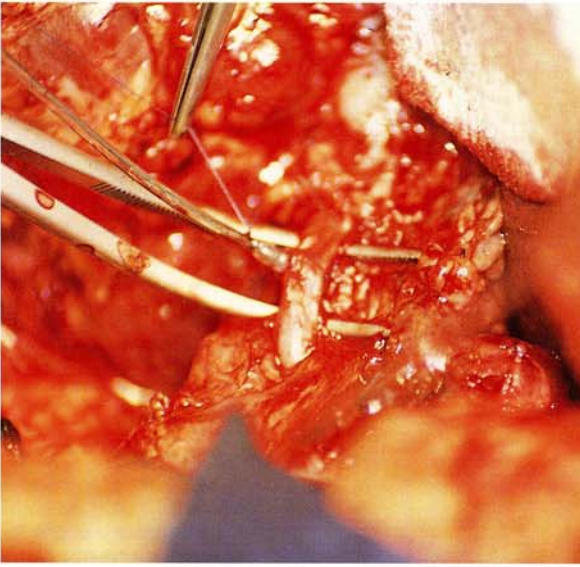


Fig. 10.7.3 **Implantation technique for Implantofix or Jet Port valve-tip catheters** through a purse-string prolene suture in a substitute right hepatic artery without a side branch

be ligated without any danger of damage to the liver. In most cases, collaterals open immediately. Substitute left or right arteries are usually cannulated with a valve-tip catheter via a prolene purse-string suture (Fig. 10.7.3). If there is early branching of the left hepatic artery, the common hepatic artery is also cannulated using a purse-string suture, while the gastroduodenal artery and all visceral branches are ligated. Finally, the abdomen is closed in layers and the catheter is exited through the midline wound. The port is placed in a subcutaneous pouch in the upper third of the midline incision. Non-metal ports (e.g. Implantofix, Jet Port) do not need to be fixed to the fascia with sutures. The silicon membranes should only be punctured with so-called "Huber needles." Before implantation and after each infusion of drugs, catheters are flushed with saline/heparin (9 : 1 ml) solution. Arterial chemotherapy is given according to the protocols either as a short-term or as a continuous long-term infusion with portable external pumps. If implantable pumps (e.g. Infusaid, Medtronic) are used, the drug of choice is FUDR, and combination chemotherapy can be performed through the side ports.

Isolated Liver Perfusion

Among the various modalities available for regional cancer treatment, ILP is the most time-consuming, demanding a 4-hour operation with the

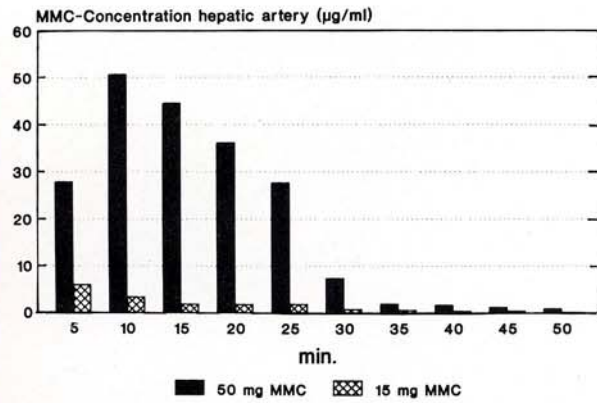


Fig. 10.7.4 **Mitomycin C levels in the perfusate** during isolated liver perfusion with 15 or 50 mg MMC

heart-lung machine. The advantages, however, are that the drug can be administered via the hepatic arterial and portal route, additional hyperthermia can be used, and complete isolation makes it possible to give total doses up to amounts which are only limited by the local tissue tolerance. ILP is the method of choice for tumors with low chemosensitivity. Drug levels in the perfusate can be adjusted to any desired range, depending only on the total dose injected into the isolated circuit (Fig. 10.7.4).

Operative Procedure

Through an abdominal midline incision, the liver, hepatoduodenal ligament and the inferior vena cava (Fig. 10.7.5) below and above the liver are exposed. Access to the intrapericardial part of the inferior vena cava is achieved by a transverse incision of the diaphragm (Fig. 10.7.6). A tourniquet tape is placed around the vein there, and above and below the renal veins. Two tapes are placed around the portal vein for cannulation in two directions, and around the common hepatic and gastroduodenal arteries (Fig. 10.7.7). Cannulation of the vena cava is achieved through a longitudinal incision below the renal veins, where a special catheter (Perfufix[®], B. Braun) is inserted (Fig. 10.7.8). This double-lumen catheter consists of two tubes, one of which collects the hepatic venous return selectively using gravity in the oxygenator of the heart-lung machine. Two lateral openings in the double-channel perfusion catheter (Fig. 10.7.9) collect the venous return from the kidneys. The distal portal vein cannulation catheter collecting the blood from the gastrointestinal tract is connected with a side hose of the liver perfusion catheter entering the central tube, thus bypassing the liver during isolated perfusion (Fig. 10.7.10). Finally, the hepatic artery is cannulated via the

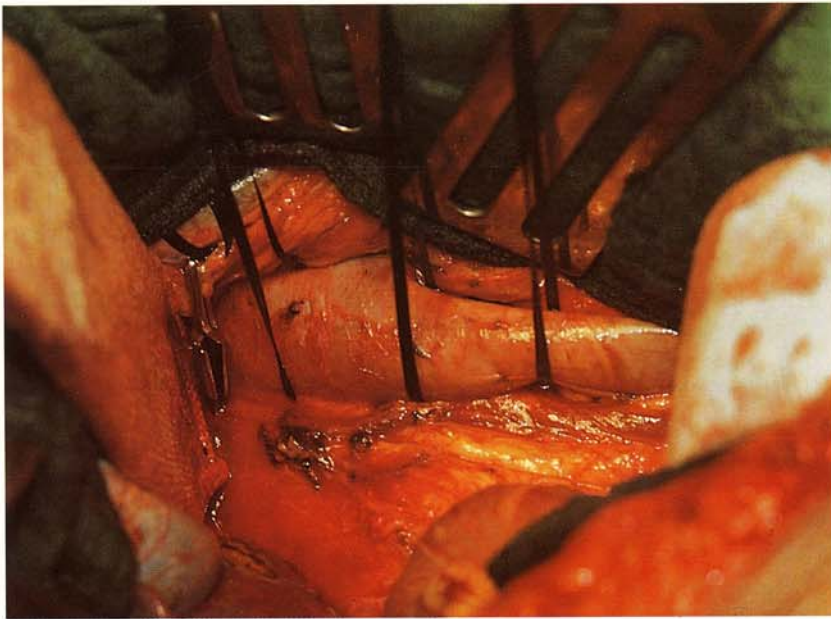


Fig. 10.7.5 Exposure of the inferior vena cava and placement of tapes, one above and two below the renal veins

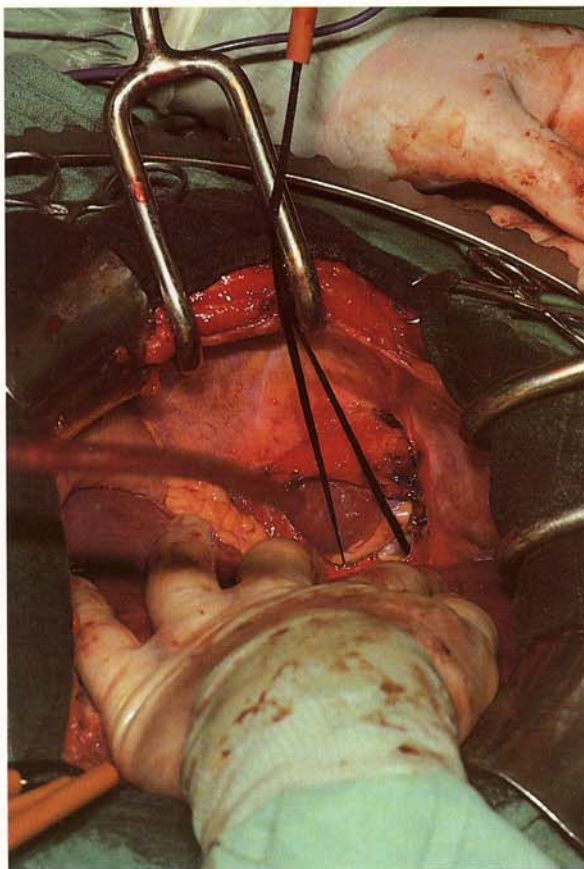


Fig. 10.7.6 A transverse incision in the diaphragm and pericardium and intrapericardial tourniquet tape around the vena cava at its entrance into the right atrium

gastroduodenal artery. If there are anatomic variations, double cannulations are performed.

Isolated bypass is started via the portal vein circuit. The portal venous flow with arterialized blood from the oxygenator is finally adjusted to about 300–400 ml/min while the hepatic arterial roller-pump flow rate is adjusted to about 100 ml/min. The cytotoxic drug is infused directly into the hepatic arterial line at a calculated speed in order to maintain the necessary drug concentration in the perfusate over a period of usually 30 min. Thus a very high area under the curve (AUC) is guaranteed during the first half of the isolation perfusion. During the second 30 min the drug, diluted in the perfusate, recirculates through both arterialized access lines. Thermister probes are placed in the right and left liver lobes and the tissue temperature is adjusted at 40°C using a perfusate temperature of 41.5°C to 42°C. At the end of a one-hour perfusion, the liver is rinsed and remaining drugs are washed out of the vascular system. The catheters are withdrawn step-by-step, and the vessels are repaired with running sutures. Cannulation and 60 min isolated perfusion are performed under systemic heparinization of the patient with 200 IU of heparin per kg of body weight. At the end of the operation, implantation of a hepatic arterial catheter for subsequent hepatic arterial infusion is standard.

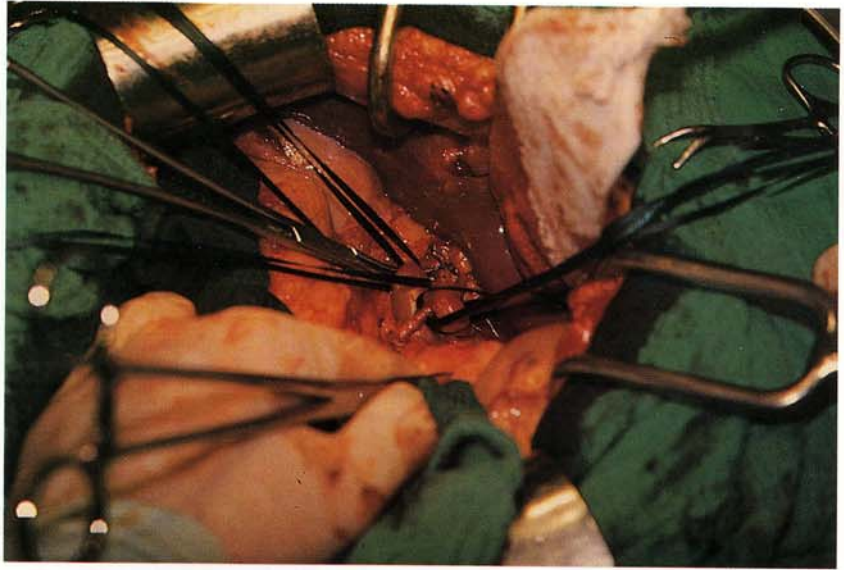

Fig. 10.7.7 Exposure of the porta hepatis, with the portal vein (two tapes), the common hepatic artery (one tape) and the gastroduodenal artery

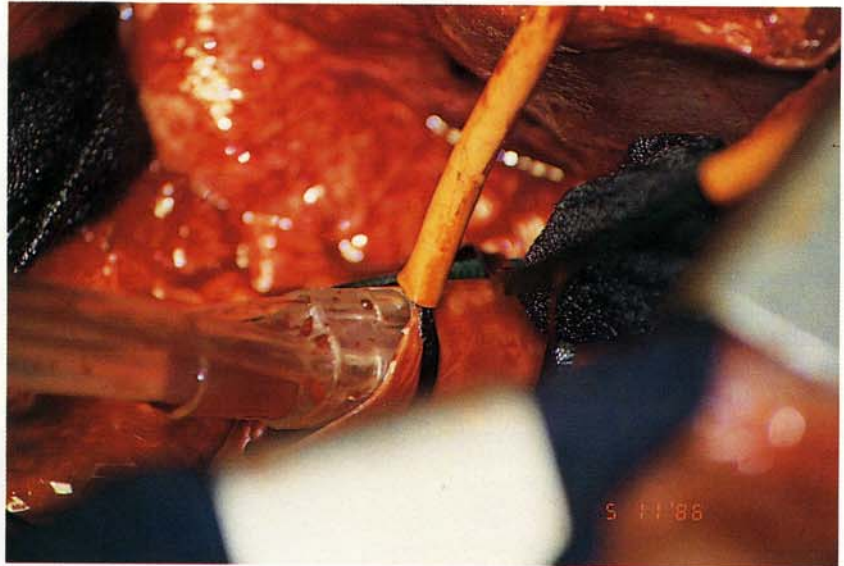


Fig. 10.7.8 Cannulation of the vena cava below the renal veins with a Perfix double-lumen catheter

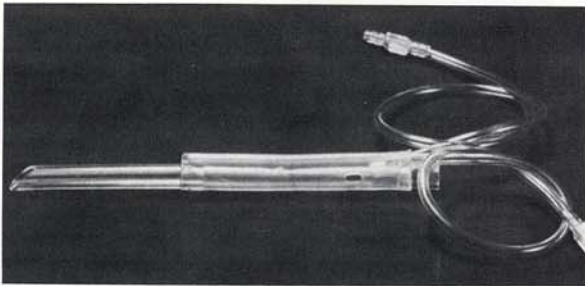


Fig. 10.7.9 Perfix double-lumen liver perfusion catheter with two lateral openings in the shunting tube

Hepatic Arterial Infusion and Filtration

Rationale of Cytostatic Filtration

By using hemofilters in regional chemotherapy it is possible to reduce the drug levels in the venous outflow behind the tumor, left over from the first pass. Thus adverse side-effects which reduce the quality of life can be avoided. In addition, by adjusting the filtration effect individually, systemic drug levels comparable to those obtained in i.v. treatment can be generated when indicated

(Fig. 10.7.11). In the hemofiltration circuit (Fig. 10.7.12), the venous blood with high cytostatic drug levels is pumped via an air trap to the hemofilter by a roller pump. Between the hemofilter and the patient, an additional air trap is fixed. By adding the substitutional volume before the hemofilter via an additional roller pump, the blood can be prediluted for higher filtration efficiency or, as demonstrated in Figure 10.7.12, postdiluted when the substitution inflow is behind the filter. After starting the filtration, the flow rates through the hemofilter should be slowly increased to a maximum volume of 300–600 ml/min. Cytostatic arterial infusion into the patient's tumor-affected region should be started when the filtrate flow has reached at least 70 ml/min. The total filtrate volume has to be adjusted to the desired conditions, such as the arterial drug concentration over the perfusion period and the tolerable maximum dose.

In our experience, Söring and Gambro filters have turned out to be an optimal system for cytostatic drug filtration when mitomycin C, doxorubicin, melphalan or cisplatin are used. A computerized cytostatic drug filtration hemoprocessor (Gambro, Lund) has the advantage that, once adjusted, it can run by itself. Instead of a hemoprocessor, however, a quite simple set-up consisting of three roller pumps for blood flow, filtration flow and volume substitution flow can be used as well. Volume balance is obtained by controlling the

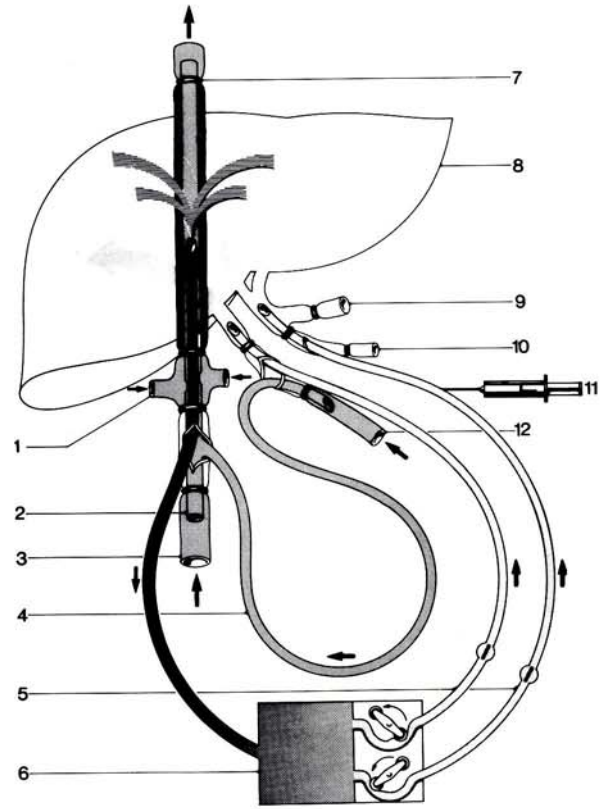


Fig. 10.7.10 The complete isolation of the liver in an extracorporeal circuit

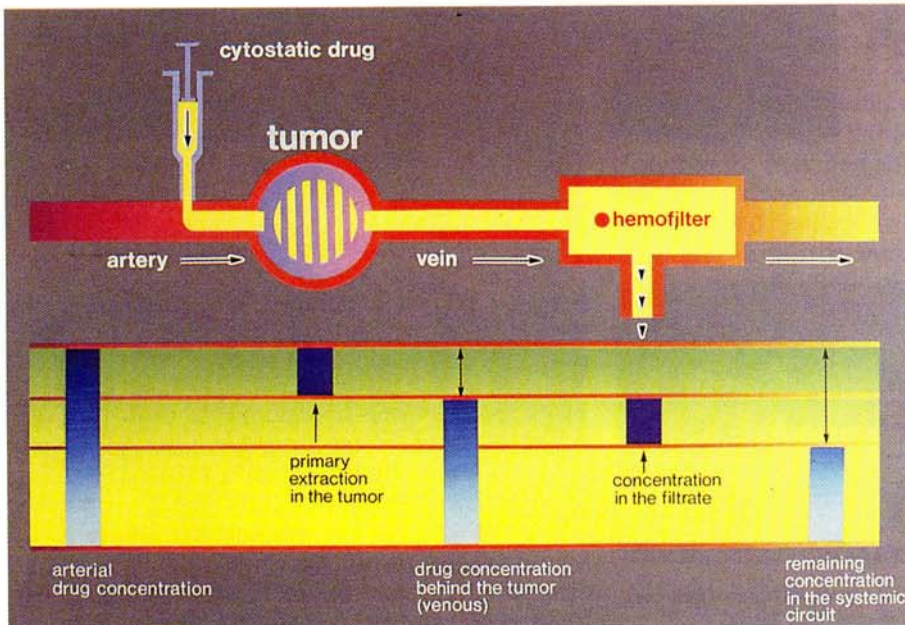


Fig. 10.7.11 Rationale of intra-arterial cytostatic infusion with venous drug filtration (from PfM, Cologne, Oncology II)

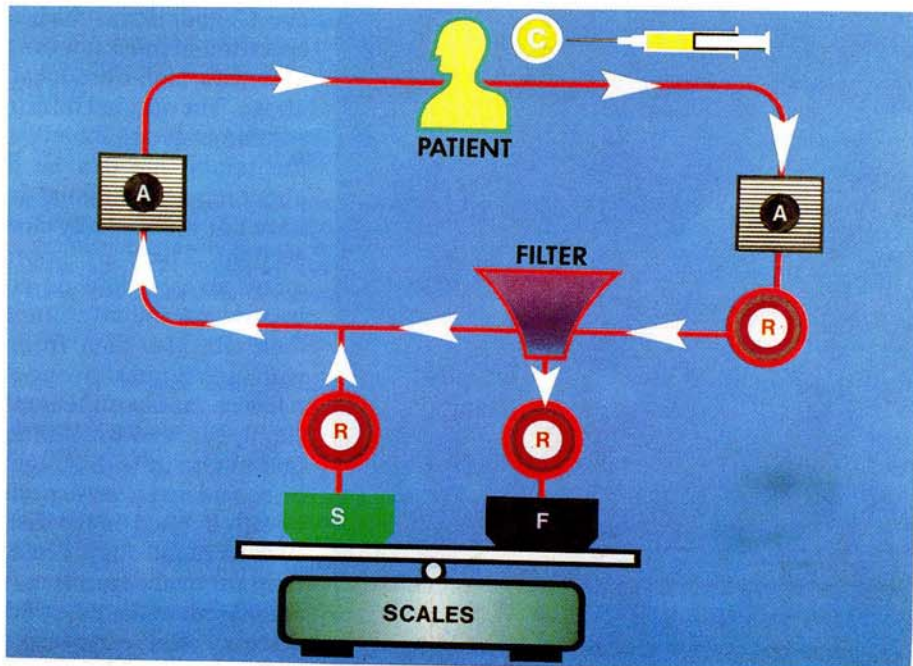


Fig. 10.7.12 System for venous drug filtration with two air traps (A), three roller pumps for blood flow through the filter (R), filtrate flow (F) and substitution flow (S). The filtrate and substitution solutions are balanced on scales

amount of filtrate and volume substitution solution on the scales. This procedure requires a greater amount of work and attention, since the patient's volume has to be balanced continuously. As a consequence, monitoring the electrocardiogram (ECG) and pulse frequency is mandatory. Leakage can be detected immediately by changes in the heart frequency.

Operative procedure

The filtration is performed with a special double-lumen catheter (PfM, Cologne), which is available in three sizes, F7, F9 and F16. The F7 and F9 catheters can be introduced into the femoral artery with the Seldinger technique, and the tip advanced to the tumor region. For intra-arterial chemotherapy of the liver with venous filtration, the tip of the catheter is positioned directly at the entrance of the inferior vena cava into the right atrium. Catheter position is controlled by X-rays at the beginning of filtration.

The large F16 catheter has to be introduced into the saphenous vein by means of a short-cut in the groin under local anesthesia (Fig. 10.7.13). Any catheter placement and filtration procedure has to be performed under systemic heparinization of the patient with 150 IU heparin/kg of body weight. After a 60 min filtration, the catheter is removed and the vessels are sutured.

Discussion

There have, up to now, been two prospective randomized trials comparing intra-arterial and intravenous chemotherapy. In both studies, colorectal liver metastases were treated with i. a. versus i. v. continuous infusion with FUDR (Hohn et al. 1987, Kemeny 1988). Although response rates and disease-free intervals were superior when FUDR was given intra-arterially, in the NCOG study (Hohn et al. 1987), the two groups were not comparable due to a cross-over of systemically treated non-responders into the arterial arm, and to local toxicity urging termination of i. a. FUDR in responders. In the Kemeny (1988) study, a significant prolongation of survival in the i. a. group was demonstrated. Furthermore, a dose-response relationship is evident when the two studies are compared, indicating that a further decrease of the FUDR dosage in order to decrease side-effects may decrease tumor toxicity as well.

It should be emphasized, however, that a study on colorectal liver metastases alone, considering only one drug whose potential efficacy is limited by local toxicity, cannot be representative of the potential advantages of the wide field of regional chemotherapy and drug targeting. In our experience in intra-arterial cancer treatment, the CR/PR

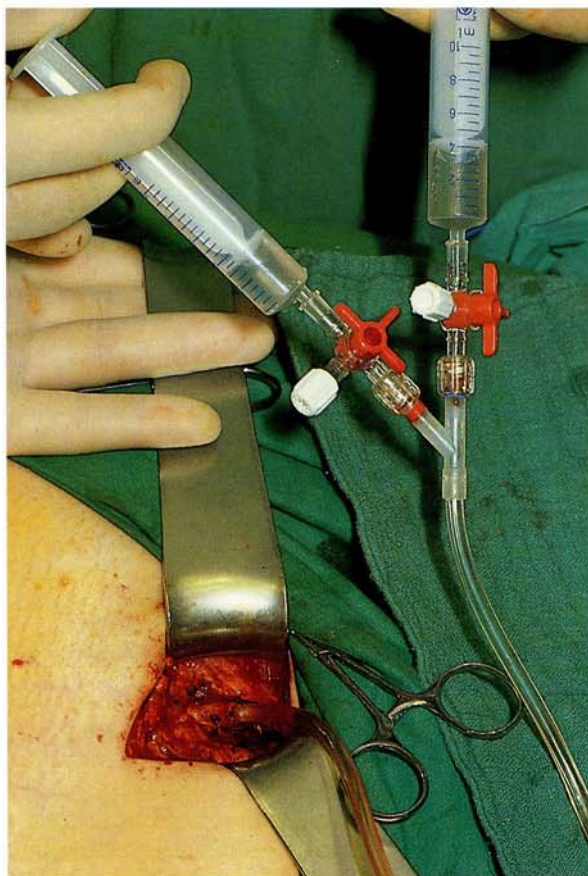


Fig. 10.7.13 Surgical placement of an F16 filtration catheter (PfM, Cologne) under local anesthesia through a longitudinal incision in the groin

ratio can be further improved by using different drugs and treatment modalities focused on the individual situation.

The fact that tumor vascularization plays a predominant role in any kind of chemotherapy with regard to the maximally achievable drug levels in tissue has not yet been taken into consideration. There are so far no data on the required minimum tissue levels in various histological types. The initial experimental and clinical data indicate that there is a marked difference in drug uptake between normal and metastatic tissue (Aigner 1988), and between intra-arterial and intraportal applications (Sjogurdson et al. 1987).

Attention has not yet been given to chemosensitivity testing for targeted chemotherapy either. It has been shown by Link et al. (1985) that tumoricidal drug concentrations and concentration \times time factors can be specifically predicted in tumor cell colonies. In non-responding tumors, a change of drugs in accordance with chemosensitivity tests may result in sudden response. Currently mitomy-

cin C and doxorubicin seem to have a broad spectrum in most tumors at concentrations achievable with high-dose local techniques as described above. The optimal infusion or perfusion technique recommended to achieve effective concentrations at the tumor site can be derived from knowledge about required minimal drug concentrations. There have not yet been any clinical trials taking this into account. There are impressive case reports from many groups showing complete remissions from hepatic arterial infusion alone. On the other hand there are also data from isolated liver perfusion with high doses showing minimal or no response in a few cases, since the metastases had a poor blood supply, as seen when blue dye was injected. These findings indicate that regional chemotherapy has to be considered a very specific method, which should be only applied on the basis of tumor characteristics such as blood supply and chemosensitivity. Long-term survival depends on whether micrometastases are present at the time of the initial treatment. Thus there is a clear, early-stage dependent indication for isolated liver perfusion. Long-term disease-free survival of up to five years in 10.8% has been observed in ILP for disseminated colorectal liver metastases (Aigner et al. 1988 b). This result might be further improved on in early-stage patients with lesions confined only to the liver, in a study based on predictive drug testing.

Conclusions

In non-resectable disseminated liver metastases, regional chemotherapy may be considered a valid therapeutic alternative. Depending on the chemosensitivity of the metastatic lesions, a local treatment modality providing medium or high drug levels is applied. Colorectal liver metastases require isolated liver perfusion or arterial infusion and drug filtration in order to achieve a high CR/PR ratio. Restitution of resectability can sometimes be obtained in primarily non-resectable hepatomas after chemoembolization or high-dose arterial chemotherapy. Carcinomas are also very sensitive to chemoembolization. In hepatomegaly from disseminated colorectal disease, HAI-F is preferable to ILP. In general, intra-arterial chemotherapy modalities offer high local efficacy with low systemic toxicity and the prospect of a good quality of life.

References

- Aigner KR. Drug filtration in high-dose regional chemotherapy. In: Aigner KR, Patt YZ, eds. *Advances in regional cancer treatment: contributions to oncology*. Basel: Karger, 1988: 261–280.
- Aigner KR, Tonn JC, Walther H, Link KH, Schwemmler K. The isolated liver perfusion technique for high-dose chemotherapy

- of metastases from colorectal cancer: two years' clinical experience. In: Van de Velde CJH, Sugarbaker PH, eds. Liver metastasis: basic aspects, detection and management. The Hague: Nijhoff, 1984: 346-357.
- Aigner KR, Walther H, Helling HJ, Link KH. Die isolierte Leberperfusion. In: Aigner KR, ed. Regionale Chemotherapie der Leber. Basel: Karger 1985: 43-83. (Beiträge zur Onkologie; vol. 21.)
- Aigner KR, Walther H, Link KH. Pharmacokinetics and pharmacodynamics of mitomycin C (MMC) in ILP and HAL. Proceedings of the third International Conference on Advances in Regional Cancer Therapy, ICRCT 87, Ulm, 1987.
- Aigner KR, Müller H, de Toma G. Mitoxantron in regional chemotherapy. In: Aigner KR, Patt YZ, eds. Advances in regional cancer treatment: contributions to oncology. Basel: Karger, 1988a: 49-57.
- Aigner KR, Walther H, Link KH. Isolated liver perfusion: surgical technique, pharmacokinetics, clinical results. In: Aigner KR, Patt YZ, eds. Advances in regional cancer treatment: contributions to oncology. Basel: Karger, 1988b: 229-246.
- Boddie AW Jr, Patt YZ, McBride CM, Wallace S, Ajani AJ, Charnsangavej C, Soski M, Levin B. MDAH surgical experience with implantable Infusaid pumps and Medtronic drug administration devices. In: Aigner KR, Patt YZ, eds. Advances in regional cancer treatment: contributions to oncology. Basel: Karger, 1988: 193-204.
- Hohn DC, Stagg RJ, Rayner AA, Lewis BJ. The NCOG randomized trial of intravenous (iv) vs hepatic arterial (ia) FUdR for colorectal cancer metastatic to the liver. Proceedings of the third International Conference on Advances in Regional Cancer Therapy, ICRCT 87, Ulm, 1987.
- Hohn DC, Shea WJ, Gemlo BT, Lewis BJ, Stagg RJ, Ignoffo RJ, Rayner AA. Complications and toxicities of hepatic arterial chemotherapy. In: Aigner KR, Patt YZ, eds. Regional cancer treatment: contributions to oncology. Basel: Karger, 1988: 169-180.
- Kemeny N. Regional chemotherapy for cancer. Proceedings: New approaches in cancer therapy. Ulm, 1988.
- Link KH, Aigner KR, Kuehn W, Roetering N, Schwemmler K. Drug testing in regional chemotherapy. Proceedings of the second International Conference on Advances in Regional Cancer Therapy, ICRCT 85, Giessen, 1985.
- Sigurdson ER, Ridge JA, Kemeny N, Daly JM. Tumor and liver drug uptake following hepatic artery and portal vein infusion. *J Clin Oncol* 1987; 5: 1836-1840.
- Skibba JL, Quebbeman EJ, Komorowski RA, Thorsen KM. Clinical results of hyperthermic liver perfusion for cancer in the liver. In: Aigner KR, Patt YZ, eds. Regional cancer treatment: contributions to oncology. Basel: Karger, 1988: 222-228.
- Stagg RJ, Chase J, Lewis BJ, Ring E, Maroney T, Venook A, Hohn DC. Chemoembolization of primary and metastatic liver tumors. Proceedings of the third International Conference on Advances in Regional Cancer Therapy, ICRCT 87, Ulm, 1987.
- Storm FK, ed. Hyperthermia in cancer therapy. Boston: Hall, 1983.